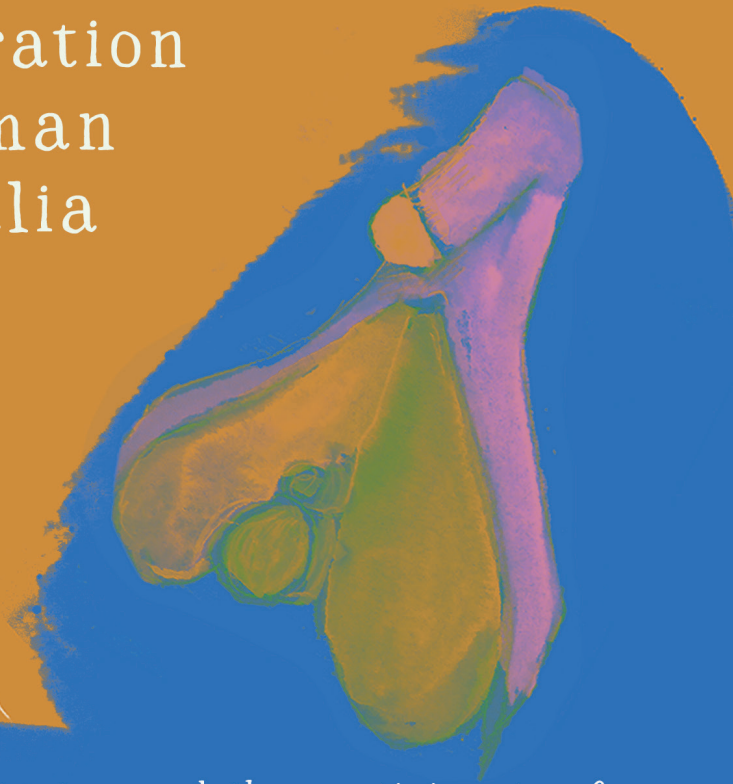


Bodies of Art:

an arts& crafts
exploration
of human
genitalia



by Dafni Petratou and the participants of
the workshop given 14 March, 2026
At the cultuurwerkplaats
(Arboretumlaan 1, Wageningen)

What did we do?

How does a vulva look like? What are the names of its parts? How are the (so called) male and female systems different? and of course.. How am I feeling discussing this?

These and many more questions we explored through this arts and crafts workshop. Questions we produced through discussion and reflection.

And that's not all we did: each one of us had an exercise: to create through collaging 2 parts of human genitalia. We focused on the shapes and structures offered by anatomy studies, but of course our artistic interpretation of them was free from limitations.

The aim was to challenge our perception on the human body and reflect on our feelings when we address a topic that's quite a taboo for most people.

This event is organized as part of the feminist festival of Wageningen.



Questions from the workshop!

Why is this still such a difficult subject to talk about?

What could the differences between 'male' and 'female sexuality be?

Which would be a good age to start with sexual education?

*How is the clitoris represented in media and cultural products?
& how would it look like?*

What beliefs did we grow

up with about genitalia, sexuality etc.?

Where do the urethra and the seminal canal join?

How can genitalia change with hormonal therapy?

What variations exist in genitalia between the two archetypes?

How would the

world be different if this was not a taboo topic?

Why are dimensions and shapes associated with qualities?

Do men experience something similar to a menstrual cycle?

Question to the clits: how invisible to people do you feel?

On the distinction between female - male genitalia and how this zine is arranged;

The workshop was based on 'official' anatomy studies which differentiate between 'male' and 'female' to describe the functions and shapes of genitalia. The truth is every single person has a unique anatomy. And if we were to create a spectrum between female and male organs, anatomies can fall anywhere within, without them necessarily being a source of pain or discomfort.

That was not addressed in itself in the studies we used. The workshop was based on another interesting fact which is well documented by anatomy studies: **that everyone's genitals are made of the same parts, organized in different ways** (quoting Emily Nagoski). Meaning that each arrangement consists of 'homologues', parts that have some differences but the same origin and often similar function. Except some parts that do tend to degenerate like the uterus and vagina in male arrangements (do then male genitals often include a small trace of an uterus? yes they do!).

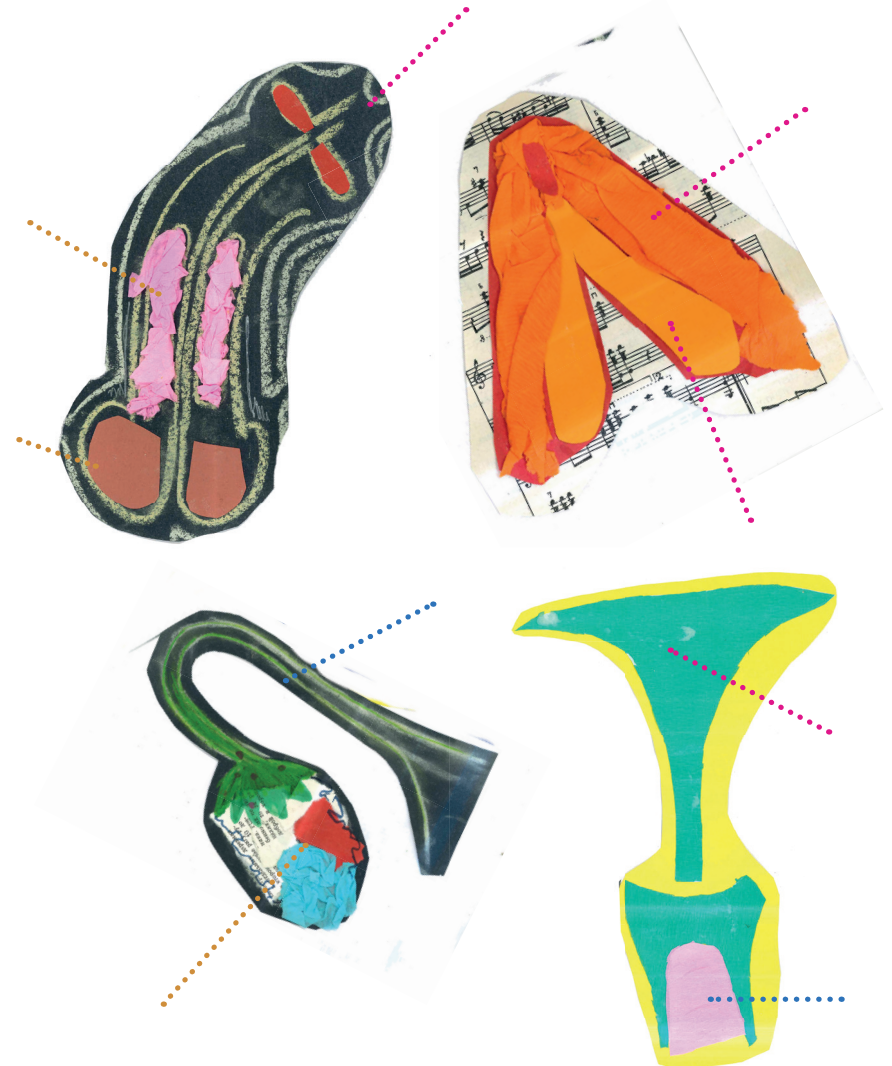
So the important information is:

- homologue parts in this zine are presented together and linked with a dotted line
- people that contributed for this zine are by no means scientists and also happen to have no intersex or transgender experience so mistakes might have to be excused.

Sources

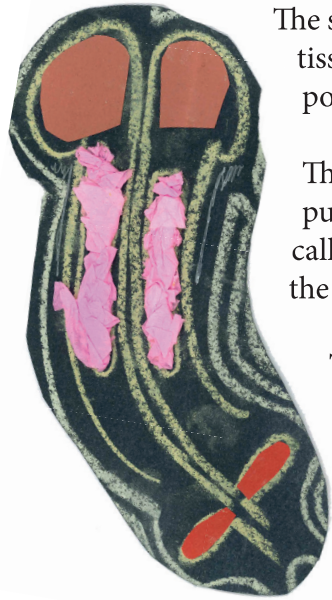
kenhub.com, uen.pressbooks.pub, nmuch.com, theory.labster.com, 'Come as you are' by E. Nagoski

Game: can you name the genitalia parts that served as inspiration for this work of art?



The penis: Corpus spongiosum, Corpora cavernosa , Bulbourethral glands

Its functions are to provide an outlet for urine and seminal fluid. The penis is divided into three parts, which you can see in the title and can also be divided differently in root shaft and glans).



The root is attaching the penis to the perineum. The shaft is the main part of the two erectile tissues: the corpus spongiosum and corpora cavernosa.

The glans penis is a portion of the corpus spongiosum. A duplicature of skin called the prepuce (foreskin) surrounds the glans.

The bulbourethral glands are found at the base of the penis, adjacent to the urethra just below the prostate. responsible for producing a pre-ejaculate fluid which is secreted during sexual arousal, neutralizing the acidity of the urethra in preparation for the passage of sperm cells.

The clitoris: Vestibular bulb , Corpora cavernosa, Bartholine's glands


It's located at the most superior part of the vulva, and has three parts of the title (also can be divided to root, shaft and glans)

The bulbs of vestibule are a pair of erectile tissues analogous to the corpus spongiosum in males. They're underneath the labia minora, sometimes considered as the root of the clitoris.

Corpora cavernosa are two parallel spongy erectile tissue chambers that form a v-shape and they're attached to the pelvic bones by a 'foot' (just like the penis).

Bartholin's glands are pea-sized with a short duct that opens into the lower vagina. One is found on each side of the vagina. They are homologous to the bulbourethral glands in the male, and function to keep the vulva moist.

Fun fact: the full network of nerves in the clitoris is mapped for the first time in 2026, in a 3D model.



Scrotum and Spongy urethra

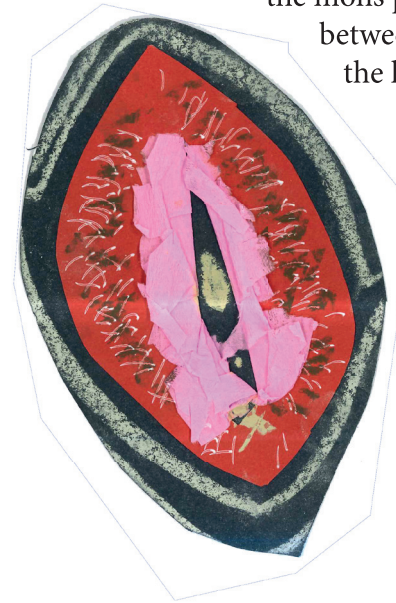The scrotum is a sac that contains the testes and lower parts of the spermatic cord. It consists of two layers: skin (superficially) and dartos fascia of scrotum (deep).

Spongy urethra is analogue to labia minora, for more information read below at the urethra section.



Labia majora and Labia minora

Labia majora are two longitudinal skin folds covered with pubic hair. They are the most lateral part of the vulva, extending from the mons pubis to the perineum. The cleft between the labia majora contains the labia minora and the vestibule*.



Labia minora are two longitudinal, thin and hairless skin folds found between the labia majora. They surround the vestibule*.

*Vestibule:


The region between the labia minora is called the vestibule. It contains the vaginal orifice, opening of the female urethra and the openings for the vestibular glands (tissues that serve lubrication, like the Bartholine's gland (see above) and the Skene's glands (see below))

Ovaries

The ovaries are disc-shaped endocrine glands, responsible for the production of eggs (ova) and the secretion of the hormones progesterone and estrogen. They are the equivalent of the male testes.

Fallopian (or uterine) tubes

The fallopian tubes are bilateral muscular organs that extend from the uterus (uterine horns specifically) to the superior poles of the ovaries. The fallopian tubes represent the usual site for fertilization.

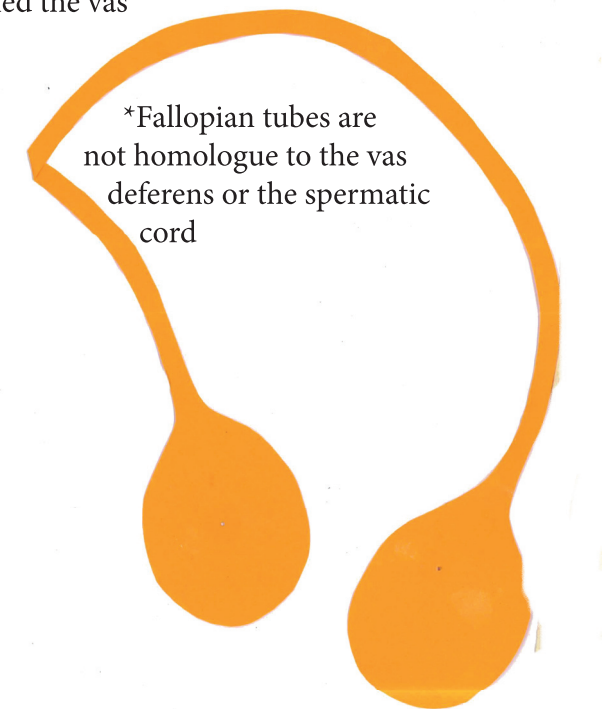


Testes, epididymis, spermatic cord, vas deferens

The testes are two oval-shaped male internal genital organs found within the scrotum. Their function is to produce sperm and the hormone testosterone.

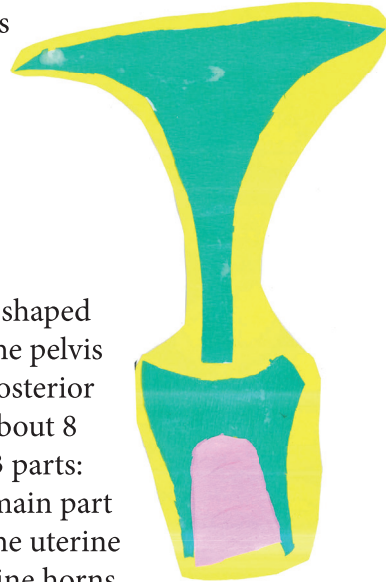
The epididymis is located on the posterior surface of the testis. It is made up of series of ducts and its main function is storage and maturation of spermatozoa.

The spermatic cord conveys the bundle of the testes and suspends them in the scrotum. The duct which carries sperm from each testis is called the vas deferens.



Vagina

The vagina is the outermost internal female sex organ. It extends from the uterus to the vulva. The upper end of the vagina is attached to the cervix of the uterus. These structures form a pouch (vaginal fornix). The lower end of the vagina (vaginal orifice) opens into the vaginal vestibule just behind the urethral orifice.



Uterus

The uterus (womb) is a pear-shaped muscular organ situated in the pelvis anterior to the rectum and posterior to the urinary bladder. It is about 8 cm long and is divided into 3 parts:

- Body (corpus) - the main part of the uterus, connected to the uterine (fallopian) tubes via the uterine horns. The body has a base (fundus) and an internal chamber (uterine cavity).
- Isthmus - the constricted part of the uterus, located between the body and the cervix.
- Cervix - the inferior portion of the uterus. It consists of two parts (supravaginal, vaginal), two openings (internal os, external os) and a cervical canal.

Urinary bladder and urethra

This organ is similar in different people, only in a male arrangement, the urethra can be divided in 3 regions:

1. Prostatic urethra- continuous with bladder and surrounded by the prostate gland. The right and left ejaculatory ducts and numerous prostatic ducts open into the prostatic urethra.
2. Membranous urethra- a short segment of the urethra that passes through the muscular pelvic floor, located between the prostatic and spongy urethra.
3. Spongy urethra- also known as the penile or pendulous urethra, is the portion of the urethra distal to the membranous urethra. It travels through the corpus spongiosum.



Prostate

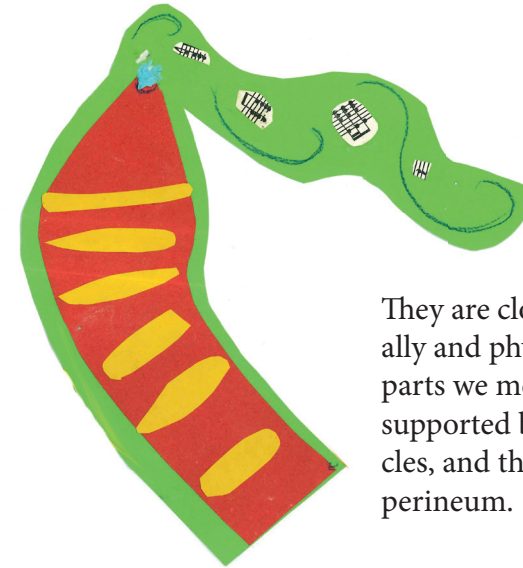
It is found inferior to the urinary bladder, and is penetrated by the urethra. The prostate function is to produce fluid secreted into the urethra during ejaculation

paraurethral glands


A pair of Skene's (paraurethral) glands, homologous to the male prostate, open into the vestibule near the external urethral orifice.



Rectum and anus



They are closely linked functionally and physically to all the other parts we mentioned. They are supported by the pelvic floor muscles, and they're part of the wider perineum.



The facilitator and designer of the zine

Participants:

Alice
Ines
David
Douwe
Ray
Manto
Hanna
Aida

Dafni Petratou is a Wageningen based visual artist and illustrator that has been surveying the human body in many different ways: figure drawing, literature research, and engagement of other various somatic activities (yoga, body-mind-centering, dancing).

You can find more information in her website:
dafnipetratou.com

Bodies of Art

for any questions/suggestions:
dafni@inkcapart.com